

8.REFERENCES

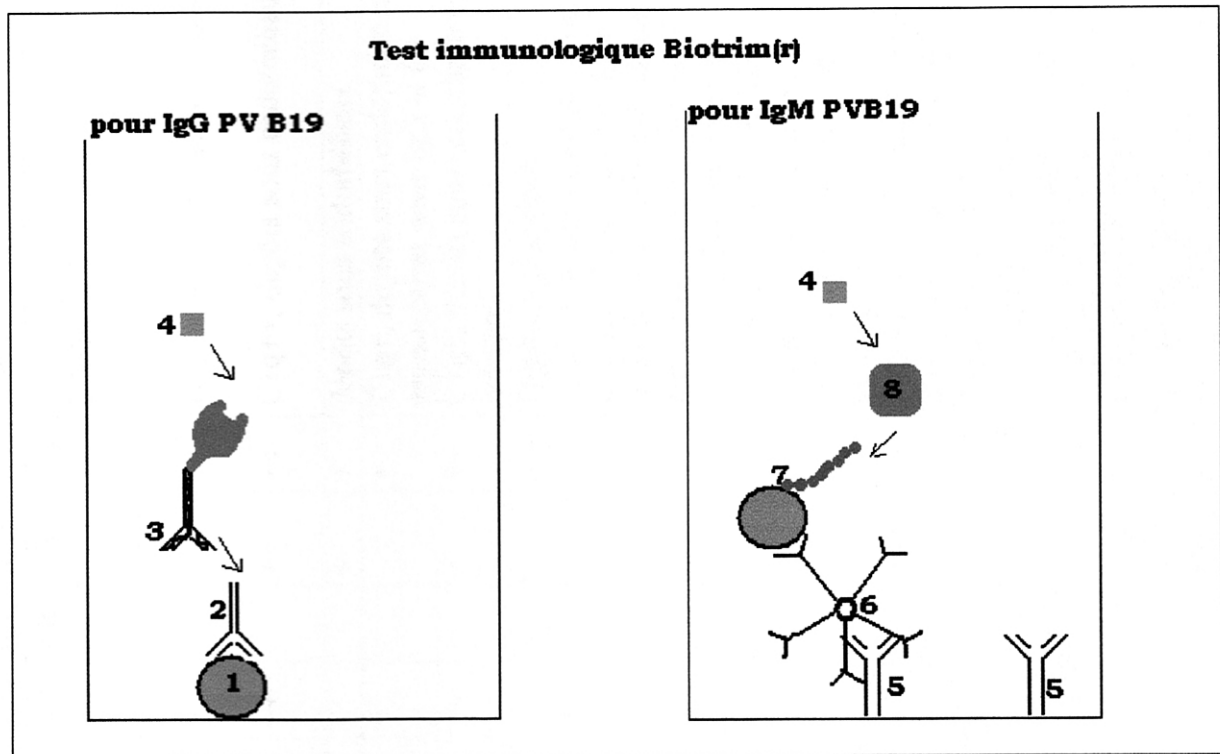
- 1** Oxford Text Book of Clinical Nephrology, II Edition, Bernardo Rodriguez-Iturbide Acute endocapillary glomerulonephritis, Chapitre 3.10 pp 613-624
- 2** Bernardo Rodriguez-Iturbide Postinfectious Glomerulonephritis AJKD 2000, Vol35, N°1, pp xivi-xiviii
- 3** Simon P et al Epidemiology of primary glomerulopathies in a French regio. Variations as a function of age in patients Nephrologie 1995; 16(2): 191-201
- 4** Fields Virology 4ème Edition 2001 Marshall E. Bloom and Neal S. Young, Parvoviruses chapter 70.
- 5** Mori S et al. Interstitial nephritis in Aleutian mink disease. Possible role of cell mediated immunity against virus-infected tubular epithelial cells. Am J Pathol 1994 Jun , 144(6): 1326-1333
- 6** Bloom ME et al. Aleutian mink disease: Puzzles and paradigms. Infect Agents Dis 1994 Dec ; 3(6): 279-301.5(abstract)
- 7** Truyen et al. Evolution of canine parvovirus involved loss and gain feline host range. Virology 1996; 215: 186-189.
- 8** Cossart YE et al. Parvovirus-like particles in human sera. Lancet. 1975 Jan 11;1(7898):72-73.
- 9** Nguyen et al. Identification and characterization of a second novel human erythrovirus variant A6. Virology 2002 sep 30; 301(2): 374-380.
- 10** Servant A, et al. Genetic diversity within human erythroviruses: identification of three genotypes J Virol. 2002 Sep;76(18):9124-9134.
- 11** Cortmore et al . Characterization and molecular cloning of a human parvovirus genome Science 1984; 226: 1161-1165
- 12** Umene K et al. The genome type of human parvovirus B19 strains isolated in Japan during 1981 differs from types detected in 1986 to 1987: a correlation between genome type and prevalence. J Gen Virol. 1990 Apr;71 (Pt 4):983-986.
- 13** Deiss V, Tratschin JD, Weitz M, Siegl G. Cloning of the human parvovirus B19 genome and structural analysis of its palindromic termini. Virology. 1990 Mar;175(1):247-254.
- 14** Luo et al. A novel protein encoded by small RNAs of Parvovirus B19 . Virology 1993.195 : 448-455
- 15** St Amand et al. Identification and characterization of family of 11 Kda proteins encoded by the human parvovirus B19. Virology 1993 192 : 121-131.
- 16** Paver WK et al Comparison of human fecal and serum parvo-like viruses. J Clin Microbiol. 1976 Jul;4(1):67-70.
- 17** Anderson et al. Human parvovirus, the cause of erthema infectiosum (fifth disease) Lancet, 1983, June 18, 1378
- 18** CG Potter et al. Variation of erythroid and myeloid precursor in the marrow and peripheral blood of volunteer infected with Human parvovirus (B19). JClvol 79, may 1987, 1486-1492
- 19** KE Brown . Erythrocyte P antigen: cellular Receptor for B19 Parvovirus. Science Vol 262. Oct 1993: 114-117
- 20** A.Kisten et al. Recombinant human parvovirus B19 vectors : erythrocyte P

- antigen is necessary but not sufficient for successful transduction of human hematopoietic cells. *J Virol* 2001. Vol 75 N°9. 4110-4116
- 21 Marcus D et al. The P blood group system: recent progress in immunochemistry and genetics. *Semin Hematol.* 1981 Jan;18(1):63-71. Review.
 - 22 KE Brown . Resistance to parvovirus B19 infection due to lack of virus receptor (erythrocyte P antigen). *N Engl J Med.* 1994 Apr 28;330(17):1192-1196.
 - 23 LLW Cooling et al. Multiple Glycosphingolipids determine the tissue tropism of parvovirus B19. *JID* 1995; 172, 1198-1205
 - 24 Ozawa et al. P. Productive infection by B19 parvovirus in human erythroïd bone marrow cells *Science* 1986; 233: 833-886.
 - 25 Ozawa et al. The gene encoding the non structural protein of B19 parvovirus may be lethal in transfected cells. *J Virol* 1988: 162: 2884-2889.
 - 26 J.M.LIU. A block in full length transcript maturation in cells non permissive for B19 parvovirus *J Virol* (1992).66 4686
 - 27 Anderson JJ et al. Experimental parvoviral infection in humans *JID* 1985 152 : 257-265
 - 28 Anderson JJ et al. Human parvoviruses *JID* 1990 161 : 603-608
 - 29 CG Potter . Variation of Erythoid and myeloid precursors in the marrow and peripheral blood of volunteer subjects infected with human parvovirus (B19). *JCI* 1987, vol 79 1486-1492
 - 30 Schwarz TF et al. Comparison of seven commercial tests for the detection of parvovirus B19 specific IgM *Zentrabl Bacteriol* 1997 Apr; 285 (4): 525-530.
 - 31 Woolf AD et al. Clinical manifestations of human parvovirus B19 in adults *Arch Med Int* 1989 ; 149 : 1553.
 - 32 Chorba T et al The role of parvovirus B19 in aplastic crisis and erythema infectiosum (fifth disease). et al. *JID* 1986 ; 154 : 383
 - 33 A. von Poblotski et al Antibodies to the nonstructural protein of parvovirus B19 in persistently infected patients : implications for pathogenesis *JID* 1995 : 172 : 1356-1359
 - 34 M. Musiani et al. Parvovirus B 19 clearance from peripheral blood after acute infection *JID* 1995 : 172 : 1360-1363
 - 35 Davenport Phase IV study of Plas + [reg]SD : HAV and PB19 safety result. *Blood* 2000 96 : 1942
 - 36 Barton SA, Nash JQ, Jones J, Sillis M, Cohen BJ Anticomplementary activity in serum samples from patients with acute parvovirus B19 infection. *J Clin Pathol.* 1995 May;48(5):493-494.
 - 37 G Kurtzman Chronic bone marrow failure due to persistent B19 Infection *NEJM* 1987 vol 317 N5 pp287-294
 - 38 G Kurtzman. PRCA of 10 years duration due to persistent parvovirus B19 Infection and its cure with immunoglobulin therapy *NEJM* 1989 vol 321 N°8 pp 519-523
 - 39 Koduri Parvovirus B19-related anemia in HIV infected patients *AIDS Patient Care STDS* 2000 Jan ; 14(1) : 7-11 (abstract)
 - 40 LS Christensen et al. Persistent erythrovirus B19 urinary tract infection in an HIV positive patient. *Clinical Microbiol & Infect* sept 2001 vol 7 N°9 p 507-508.
 - 41 Athol J Ware et al. Resolution of chronic Parvovirus B19 induced anemia by use of HAAT, in patient with AIDS *Clin Inf Dis* 2001 ;32,e122-e123
 - 42 B Crowley red cell aplasia due to parvovirus B19 in a patient treated with alemtuzumab. *Brit J Haematol.* 2002.119.279-280

- 43 J W Hsu Parvovirus B19 associated PRCA in chronic GVHD Brit J Haematol. 2002.119.280-281
- 44 BJ Cohen Human parvovirus infection in early rheumatoid and inflammatory arthritis Annals Rheumatic Diseases 1986.45.832-838
- 45 I Spreyer et al. Human parvovirus B19 infection is not followed by inflammatory joint disease during long term follow up . Retrospective study of 54 patients. Clin Exp Rheum 1998 16.576-578
- 46 DG White Human Parvovirus arthropathy Lancet 1985 fer23, 419-420
- 47 DM Reid Human parvovirus associated arthritis : a clinical and laboratory description. Lancet 1985 fer23, 422-425
- 48 M Soderlund Persistence of Parvovirus B19 in synovial membranes of young patients with and without chronic arthropathy Lancet 1997 vol 349 april 12.
- 49 H Tsuda Liver dysfunction caused by parvovirus B19 AJG 1993 sept 1463
- 50 Darel S Pardi et al. Hepatitis associated aplastic anemia and acute parvovirus B19 Infection : a report of two cases and review of the literature AJG 1998 vol 93 N°3 : 468-470
- 51 Sokal EM et al. Acute parvovirus B19 infection with fulminant hepatitis of favourable prognosis in young children Lancet 1998 ; 352 : 1739.
- 52 KE Brown Hepatitis -associated aplastic anemia NEJM 1997 vol 336 N15. 1059-1063
- 53 Langnas et al. Parvovirus B19 as a possible causative agent of fulminant liver failure and associated aplastic anemia Hepatology 1995 ;22 :1661-1665
- 54 YS Shan et al. Fibrosing cholestatic hepatitis possibly related to persistent parvovirus B19 infection in a renal transplant recipient NDT 2001 16 : 2420-2421
- 55 S Arista . Parvovirus and « cryptogenic » chronic hepatitis Letter to the editor 375-376
- 56 C Ferri.al. Parvovirus B19 infection of cultured skin fibroblasts from systemic sclerosis patients : comment on the article by Ray et al.
- 57 Maini R, Edelstein C. Uveitis associated with parvovirus infection. Br J Ophthalmol. 1999 Dec;83(12):1403-1404.
- 58 Cioc et al. parvovirus B19 associated adult Henoch Schon purpura J Cutan Pathol 2002 Nv 29 (10) : 602-607
- 59 Kuntal Chakravaty C. Systemic vasculitis and atypical infection : report of two cases Postgrad med J 1999 ; 75.544-556.
- 60 ML Schmid Parvovirus b19 and glomerulonephritis in healthy adult Annals of internal medicine 18 avril 2000 682
- 61 GS Bleumink Human parvovirus B19 and renal disease ? Neth J Med 2000 vol 56 Issue 4 April 2000 Pages 163-165.
- 62 F Diaz Glomerulonephritis and henoch-Schoenlein purpura associated with acute parvovirus B19 infection Clinical Nephrology Vol 53 N 3/2000 237-238
- 63 WS Edward et al. Hemolytic uraemic syndrome human following human parvovirus infection in a previously fit adult.NDT 1999 14 : 2472-2473
- 64 Komatsuda et al. A Endocapillary Proliferative Glomerulonephritis in a Patient with parvovirus B19 AJKD 2000 vol 36 N°4 october : 851-854
- 65 Y Mori et al. Association of parvovirus B19 infection with acute glomerulonephritis en healthy adults : case report and review of the literature clinical Nephrology Vol 57 N°1/2002 (69-73)

- 66 Y Iwafuchi et al. Acute endocapillary proliferative glomerulonephritis associated with human parvovirus B19 infection *Clinical Nephrology* N° 3/2002(246-250)
- 67 Nakazawa et al. Acute Glomerulonephritis after human parvovirus B19 Infection. *AJKD* 2000, Vol 35 (N°6) E31
- 68 Ohtomo et al. Nephrotic syndrome associated with human parvovirus B19 infection *Pediatr Nephrol* 2003 Mar 18.(3): 280-282
- 69 DE Wesson The initiation and progression of sickle cell nephropathy *Kidney Int* Vol 61(2002):2277-2286.
- 70 K J J Wierenga et al. Glomerulonephritis after human parvovirus infection in homozygous sickle cell disease *Lancet* 1995 Vol 346 475-476
- 71 Tanawattanacharoen Parvovirus B19 DNA in kidney Tissue of Patients with focal segmental glomerulosclerosis *AJKD* vol 35 N°6 pp 1166-1174
- 72 A Moudil Detection of parvovirus B19 DNA in renal biopsies of patients with idiopathic collapsing glomerulopathy. *JASN* 1997, 94A, A0447(Abstract)
- 73 Murer et al. Thrombotic microangiopathy associated with parvovirus B19 Infection after renal Transplantation. *J A S N* 2000 11 1132-1137.
- 74 Barsoun et al. Treatment of Parvovirus B19 (PV B 19) Infection allows for succesful kidney tranplantation without disease recurrence. *AJ Transplant.* 2002; 2:425-428
- 75 Tolfvenstam T Mapping of B cell epitopes on human parvovirus B19 non structural and structural proteins *Vaccin* 2000 Nov 22 ; 19 (7-8) : 758-763. *Vaccine* 2000 Nov 22 ; 19(7-8) : 758-763 (Abstract)
- 76 Musiani et al Immunoreactivity against linear epitopes of parvovirus B19 structural proteins . Immunoinnace of the aminoterminal half of the uneique region of VP1 *J Med Virol* 2000 Mar 60 (3) : 347-352 (Abstract)
- 77 W Ripley et al. Safety and immunogenicity of recombinant parvovirus B19 vaccine formulated with MF59C.1 *JID* 2003 ; 187 : 675-678.
- 78 Fraussila T Helper Cell mediated In vitro Responses of Recently and Remotely Infected Subjects to a candidate recombinant vaccine for human parvovirus B19. *JID* 2001 ; 183 : 805-809
- 79 Tsinalis et al. Acute renal failure in renal allograft recipient treated with intravenous immunoglobulin. *AJKD* 2002 sep 40 (3) 667-670.
- 80 Lee et al. parvovirus B19-related acute hepatitis in an immunosuppressed kidney transplant *NDT* 2000 Sep ; 15(9) 1486-1488
- 81 Moudil et al. Parvovirus B19 infection related complications in renal transplant recipients, treatment with intravenous immunoglobulin. *Transplantation* 1997; 64: 1847-1850.
- 82 R Mareschal Desandes et al. Succesful treatment of chronic Parvovirus B19 infection by high dose immunoglobulin. *Clinical Nephrology* vol 59 N°4/2003 311-312
- 83 Pamidi et al. Human parvovirus B19 infection presenting as persistent anemia in renal transplant recipients. *Transplantation* 2000 June 27; 69 (12) 2666-2669
- 84 Zolnourian et al. Parvovirus B19 in kidney transplant patients *Transplantation* 2000 May 27 ; 69(10) : 2198-2202
- 85 RJ Glassock et al. (80) immune complex induced glomerular injury in viral disease : an overview *Kidney Inetrnational* Vol 40 suppl 35 (1991), pp S5-S7.
- 86 Abkowitz L et al. Clinical relevance of parvovirus B19 as cause of anemia in patients with human Immunodeficiency Virus Infection, *JID* 1997; 176: 269-273.

Appendice I



1 : Protéine VP2 ; 2 : IgG du patient, 3 : IgG de lapin anti IgG Humaine couplée à une peroxydase, 4 : tétraméthylbenzène, 5 : : IgG de lapin anti IgM Humaine, 6 : IgM du patient, 7 : Protéine VP2 biotinilée, 8 : straptvidine-HRP(peroxydase).

Résultats des biopsies effectuées chez des patients atteints de PV B19

Auteurs	Microscopie Optique		Immunofluorescence					Matériel Viral
			IgG	IgA	IgM	C3	Autres	
Chakravaty (59)	F48	GN mésangioproliférative	NR	NR	NR	NR		
Schmid (60)	F32	GN proliférative	+	+		+	Dépôts diffus	Ag PV B19 : neg
Bleunink(61)	F31	/						
	F34	/						
	H71	GN endocapillaire mésangioproliférative, exsudative diffuse	+		+	+	Dépôts le long membrane basale	
Nakazawa(67)	F30	GN endocapillaire avec infiltrat leucocytaire diffus	++		++	++	C1q++, dépôts sous endothéliaux	Ag PV B19 : pos PCRt DNA : pos
	F37	GN endocapillaire avec infiltrat leucocytaire focal			+	+	dépôts sous endothéliaux	PCRt DNA : pos
	F39	GN endocapillaire avec infiltrat leucocytaire focal	+			+	C1q+, dépôts sous endothéliaux, segmentaires pour IgG et C3	PCRt DNA : pos
	F27	GN endocapillaire avec infiltrat leucocytaire diffus +croissant	++		+	++	C1q+, dépôts sous endothéliaux, croissants	PCRt DNA : pos
Diaz (62)	F62	GN segmentaire et focale proliférative		+		+	Dépôts mésangiaux	
Edward(63)	H34	GN mésangioproliférative avec lésion nécrosante et thrombi artériolaires	+	+	+		C1q+, + lésions nécrotiques sans croissant, 1+ artériolaires avec thrombose, Œdème interstitium + infiltrat leuco. focal luminal	
Kamatosuda (64)	F45	GN endocapillaire exsudative	++	+	++	++	Fib++, dépôts capillaires et mésangiaux + N .I . en ME : rares et petits Humps sinon sous endothéliaux et mineur dans mésangium	Ag PV B19 : pos més+mb b
Mori (65.)	F20	GN endocapillaire exsudative	+	+	+++	++	Œdème interstitiel, dépôts sous endo ; pas de dépôts sous épi (humps) ni mésangiaux	
Iwafuchi (66)	F36	GN endocapillaire exsudative diffuse	+		++	+	Mésangiolyse focale, lésions thrombotiques segmentaires, IF : capillaire et mésangium, confirmé en ME : pas de dépôts sous épithéliaux (Humps)	PCRt DNA : pos
Cioc (58)	F64	GN mésangioproliférative		++			Dépôts granulaires diffus	RNA PB19 : pos

GN : glomérulonéphrite, Ag PV B19 : recherche immunohistologique de l'antigène parvovirus B19 ; neg : négatif., PCRt DNA : PCR d'ADN du PV B19 à partir d'extrait de tissu rénal ; pos : positif . RNA PB19 : ARN du PB19 recherché par reverse transcriptase PCR in situ. Fib : fibrinogène